



How does bovine herpes mammillitis spread?

Bovine herpes mammillitis (BHM) is an ulcerative dermatitis of the teats, udder and area between the vulva and anus (Turner et al 1976). Outbreaks may make milking very difficult, and are often accompanied by concurrent mastitis.

BHM is caused by bovine herpesvirus 2 (BHV-2). The virus can live away from the host, persisting for more than 100 days at room temperature, and surviving freezing and thawing. It is inactivated at pH of 3 and by iodophor disinfectants.

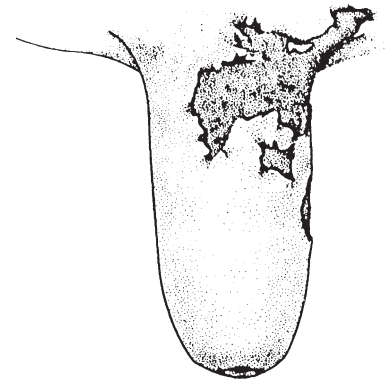
Two epidemiological patterns are seen: in some outbreaks most of the herd is affected over a period of up to four months; in others the disease appears only in first calf heifers (indicating that older cows have been exposed and established some immunity).

Observations in the United Kingdom and Australia have indicated that insects may act as vectors. The virus must be deposited in the deep layers of the skin, so it is unlikely that a correctly functioning milking machine would be an important predisposing factor for spread. Nevertheless, liners will carry large quantities of virus shed at the peak of the disease and could introduce the virus to uninfected cows if teat lesions were present.

It is presumed that the virus spreads by local extension on the skin. Affected cattle usually show no systemic illness although a mild fever may occur.

Teats develop multiple, raised, oedematous plaques of 1-2 cm with or without vesiculation. The lesions may coalesce and cover a large part of the teat. The surface then sloughs leaving raw ulcers with sharp edges, which are subsequently covered with dark coloured scabs. The scabs dry and finally detach, often without leaving scars. If the whole surface of the teat has been affected, the detaching scab may come away in a single cast that resembles a thimble in appearance. Mild lesions heal in about 10 days but some ulcers may persist for months. Lesions that occur on the udder or above the vulva tend to be more diffuse and superficial. Mastitis may occur if the teat-ends are affected.

Like all herpes viruses, BHV-2 remains latent and may recur (e.g. after corticosteroid treatment). Higher incidence around calving may be associated with the immunosuppression associated with parturition.



Bovine herpes mammillitis

Clinical diagnosis is made on the presence of characteristic lesions (but must be differentiated from pseudocowpox). Confirmation can be achieved by virus isolation, or demonstration of virus in vesicle fluid, swabs or biopsy material taken at the peak of the infection. Isolation can be difficult if lesions are more than seven days old, or iodophors have been used. Recovered animals may have a raised titre for up to two years.

There is no specific treatment for BHM although application of crystal violet dye has a good reputation in helping alleviate signs (Radostits et al 1994). To facilitate milking, a water miscible antibiotic ointment may be applied before the teatcups are put on (ensuring milk is withheld from the vat), followed by an astringent after milking.

Natural infection leads to immunity that lasts for about one year, but no commercial vaccine is available.

Humans do not appear to be susceptible to infection with BHV-2.

Key papers

Radostits OM, Blood DC, Gay CC. Viral diseases characterized by skin lesions. In: Veterinary Medicine. Chapter 22, 8th edition. Bailliere Tindall, London, 1994:1127-1137.

Turner AJ, Morgan IR, Sykes WE, Nicholls WA. Bovine herpes mammillitis of dairy cattle in Victoria. Aust Vet J 1976;52:170-173.