



What do teat warts look like and how are they treated?

Bovine papilloma viruses cause teat warts. Six separate virus strains have been identified that differ in appearance and cause warts in different anatomical areas (Radostits et al 1994). On teats, different strains cause 'rice grain' flat white warts (BVP-5), frond-like papillomas that protrude in a ragged fringe of up to one centimetre in length (BVP-6) and fibropapillomas that protrude from the teat surface (BVP-1).

In general, young animals are very susceptible to papilloma viruses, and usually build up immunity (from apparent or inapparent infection) before they enter the milking herd. In older cattle, papillomas are usually confined to the udder and teat and tend to increase in frequency with age.

Spread is from one animal to another, with virus usually entering through skin abrasions. Teatcup inflations and milkers' hands help transfer the virus from one cow to the next. The live virus is relatively robust, and will remain fully viable at room temperature for over three weeks.

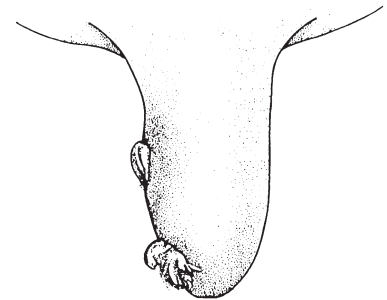
Warts can interfere with the function of the inflations and can, in some cases, block the teat canal. If they become damaged, they can serve as home for a number of mastitis pathogens (particularly *Staph aureus* and *Strep dysgalactiae*). They can also make it difficult to keep the teat clean.

Most warts are self-limiting and disappear within 5-6 months. The frond type can be physically removed. If there is a major problem in a herd, an autogenous vaccine can be made from wart tissue from cows in the herd. Type-specificity is high, so vaccines must include all serotypes and tissue types responsible for the outbreak. The response of the low, flat warts to vaccination is relatively poor.

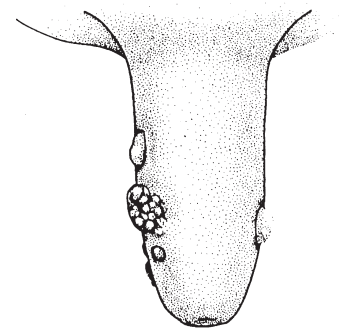
Iodine teat disinfectants with emollients are recommended to keep teat skin healthy and keep damaged warts clean.

Key papers

Radostits OM, Blood DC, Gay CC. Viral diseases characterized by skin lesions. In: Veterinary Medicine, Chapter 22, 8th edition. Bailliere Tindall, London, 1994:1127-1137.



Fillform warts



Nodular warts

